



Applied anatomy of the elbow

CHAPTER CONTENTS

Joints and ligaments	e91
Joints.	e91
Ligaments	e92
Biomechanical aspects	e92
Flexion–extension	e93
Pronation–supination	e94
Muscles and tendons	e94
Flexor muscles.	e94
Extensor muscles	e94
Supinator muscles.	e96
Pronator muscles	e96
Muscles controlling wrist movement	e98
Nerves	e99
Ulnar nerve.	e99
Median nerve	e99
Medial cutaneous nerve of the forearm	e100
Radial nerve	e100
Bursae	e101

Joints and ligaments

The elbow joint helps the hand to approach or move away from the body, whatever the arm position resulting from shoulder movement. It consists of three ‘joints’, which lie within one joint capsule and together have two separate functions.

Joints

The three ‘joints’ are the humeroulnar, the humeroradial and upper radioulnar joint (Figs 1–3, see Putz, Fig. 307). Their two

functions are flexion/extension, which is performed at the humeroulnar and humeroradial joints, and pronation/supination, which takes place at the upper radioulnar joint in close association with the lower radioulnar joint.

The three joints work closely together and make pronation and supination movements possible whatever the extent of flexion or extension of the elbow:

- The humeroulnar joint acts as a hinge. The articular surfaces on the humerus are the spool-shaped trochlea with, proximal to it, the coronoid fossa (ventral aspect) (see Gosling et al, Fig. 3.89) and the olecranon fossa (dorsal aspect) (see Gosling et al, Fig. 3.90). The other part of the joint is formed by the olecranon, with its trochlear notch and its olecranon (proximal) and coronoid (distal) processes.
- The humeroradial joint – a ball-and-socket joint – consists of (a) the spheroidal capitulum of the humerus and (b) the proximal surface of the head of the radius. Proximal to the capitulum lies the radial fossa and beside it a capitulotrochlear sulcus (between capitulum and trochlea). The articular facet of the radius, with which the proximal part of the humeroradial joint articulates, is at the top of the head of the radius. This facet exactly follows the shape of the humeral capitulum. Because it articulates with the capitulotrochlear sulcus at the ulnar side, it allows pronation–supination movements as well.
- The upper radioulnar joint is a trochoid (cone-shaped) joint. The circumference of the head of the radius articulates with the radial notch of the ulna.

The three joints lie within the same lax joint capsule, which is spanned by muscular fibres of the brachialis, triceps and anconeus muscles.

At the distal end of the humerus lie the two epicondyles, of which the medial one is more developed than the other. They are both extracapsular.

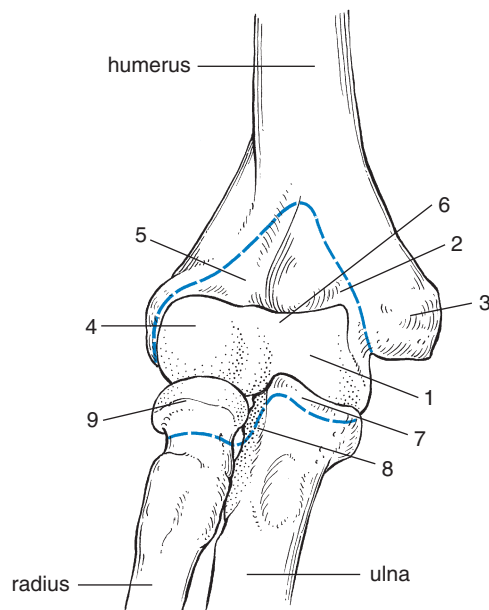


Fig 1 • Humeroulnar and humeroradial joints (anterior view). The dotted line shows the insertion of the joint capsule. On humerus: 1, trochlea; 2, coronoid fossa; 3, medial epicondyle; 4, capitulum; 5, radial fossa; 6, capitulotrochlear sulcus. On ulna: 7, coronoid process; 8, radial notch. On radius: 9, radial head.

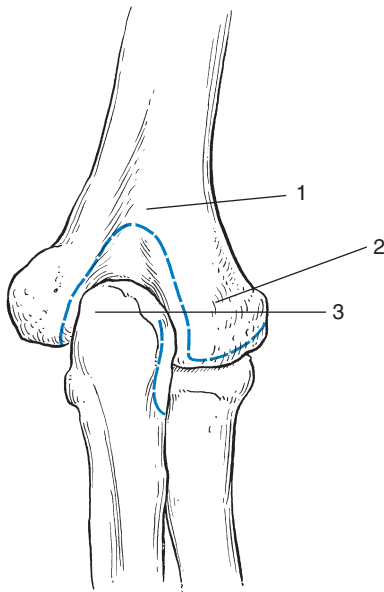


Fig 2 • Humeroulnar and humeroradial joints (posterior view). The dotted line shows the insertion of the joint capsule. On humerus: 1, olecranon fossa; 2, lateral epicondyle. On ulna: 3, olecranon process.

Ligaments

The capsule is reinforced by strong lateral ligaments (Fig. 4):

- *The medial collateral ligament* has an anterior part, which runs from the medial epicondyle of the humerus towards the annular ligament, a middle part towards the coronoid

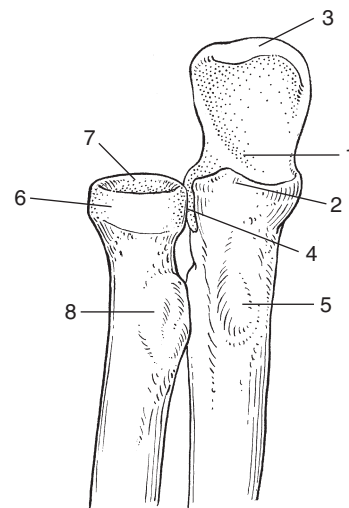


Fig 3 • Upper radioulnar joint. On ulna: 1, trochlear notch; 2, coronoid process; 3, olecranon process; 4, radial notch; 5, ulnar tuberosity. On radius: 6, circumference; 7, articular facet; 8, radial tuberosity.

process, and a posterior part, directed towards the olecranon. All three parts are reinforced by an oblique band (ligament of Cooper) distally on the ulna.

- *The lateral collateral ligament* connects the lateral epicondyle to the radial annular ligament (anteriorly via the radial collateral ligament and posteriorly via the lateral ulnar collateral ligament which inserts at the supinator crest of the ulna) and is interwoven with the superficial extensor muscles.

These ligaments help to maintain the articular surfaces in contact with each other. They also limit lateral movements. Other ligamentous structures are:

- *The radial annular ligament*, a U-shaped fibrous collar, covered with cartilage at its inner aspect, joins the radial head to the proximal ulnar extremity so that they can articulate. It plays an important role in pronation–supination (see Gosling et al, Fig. 3.93).
- *The quadrate ligament* attaches the radial neck to the distal aspect of the radial notch of the ulna.
- *The oblique cord* extends inferolaterally from the lateral border of the tuberosity of the ulna to the radius, just below its tuberosity (see Putz, Fig. 315). It prevents downwards movement of the radius.
- *The interosseous membrane* (see Putz, Fig. 315) and the oblique cord join the two bones of the forearm to prevent any longitudinal movement and assist as a fulcrum in pronation–supination (i.e. diagonal rotation). They are both syndesmosis connections.

Biomechanical aspects

The distal extremity of the humerus is a fork, the axis of its articular surfaces running through the humeral capitulum and trochlea.

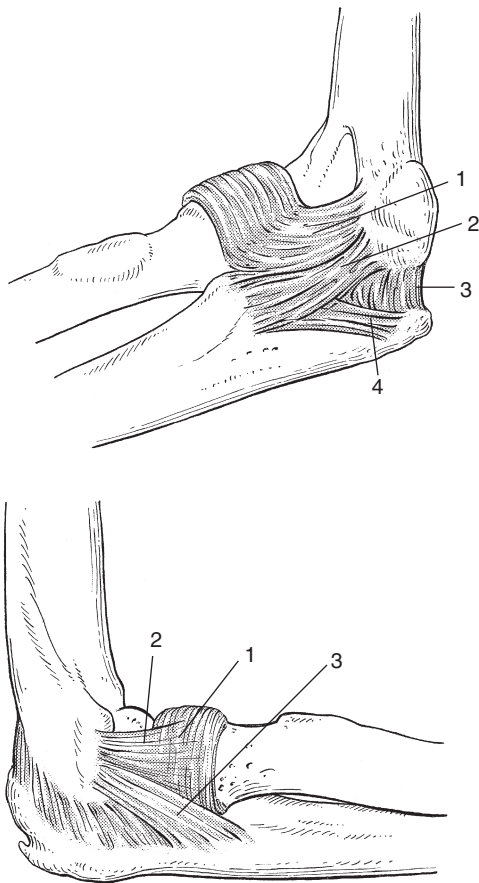


Fig 4 • The medial (upper) and radial (lower) collateral ligaments. Upper: 1, anterior part; 2, middle part; 3, posterior part; 4, ligament of Cooper. Lower: 1, annular ligament; 2, radial collateral ligament; 3, lateral ulnar collateral ligament.

The coronoid fossa, into which the coronoid process of the ulna fits, as is the case for the olecranon fossa and olecranon process, together with the forward projection of both the lower humeral and the upper ulnar extremities, allows a considerable range of flexion–extension between forearm and upper arm.

Flexion–extension

The trochlear surface of the humerus articulates with the trochlear notch of the ulna along an imaginary line A–A' which runs slightly oblique (downwards and outwards) in its posterior course. This obliquity explains the physiological valgus position of the elbow in extension (Fig. 5). In its anterior course, the axis of movement is horizontal: therefore, in flexion, the forearm lies exactly in front of the upper arm. There are, of course, individual differences.

Extension is mainly limited by the olecranon abutting against the posterior aspect of the humerus in the olecranon fossa (Fig. 6) and by stretching of the anterior part of the joint capsule. The forearm then usually lies in line with the upper arm, except in most women and in some men, in whom the elbow may sometimes overextend. This overextension is the result of

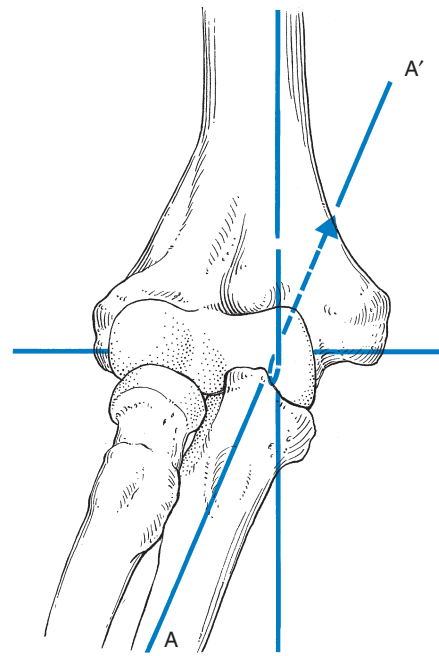


Fig 5 • The physiological valgus position. Oblique line is A–A' (see text).

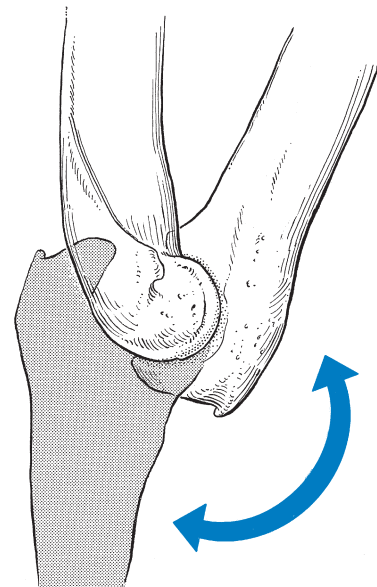


Fig 6 • The range of flexion–extension movement.

the format of the olecranon fossa and process. The end-feel of this movement is hard.

Flexion stops when, at the end of the range, the muscular masses of the upper arm and forearm come into contact with each other. The end-feel is, of course, hard in those cases in which the muscles are very poorly developed, because the movement is then stopped by the other limiting factors: (1) the contact between (a) the coronoid fossa of the humerus and the coronoid process of the ulna and (b) the head of the

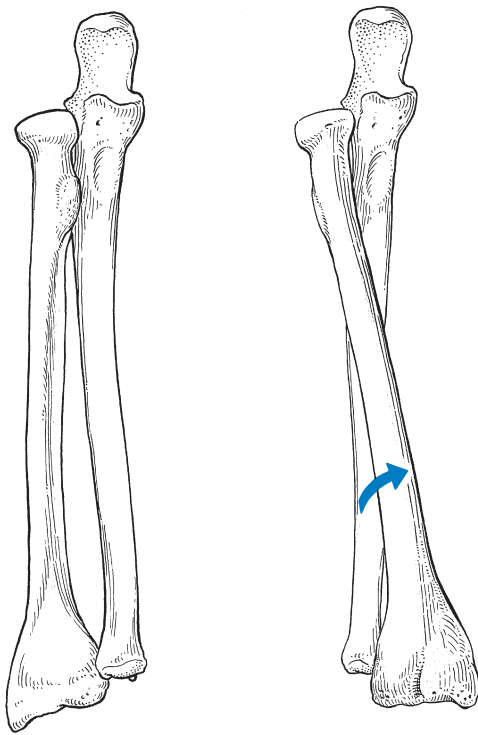


Fig 7 • Supination–pronation.

radius and the radial fossa of the humerus, as well as (2) the tension in the posterior capsule.

Pronation–supination

Pronation–supination takes place mainly in the joint formed by the radial head and the osteofibrous ring, which contains the radial notch of the ulna together with the inner aspect of the annular ligament. However, there is also movement between (a) the head of the radius and (b) the capitulum of the humerus and the capitulotrochlear sulcus.

Pronation–supination is the result of a combined action of the proximal and distal radioulnar joints, which are coaxial. Movement takes place around the longitudinal axis of the forearm, which runs from the facet on the head of the radius to the styloid process of the ulna.

Both movements can best be measured with the elbow held at a 90° angle in order to prevent compensatory rotations of the upper arm. Starting from the intermediate position with the hand vertical and the thumb pointing upwards, the supination has a range of 90°. In full supination the two bones lie parallel to each other. The limiting factor is purely ligamentous (interosseous membrane, oblique cord and anterior ligament of the distal radioulnar joint) and explains the elastic end-feel. The oblique cord prevents a downwards shift of the radius.

During pronation the radius crosses over the ulna (Fig. 7). This is possible only because of the direction of the fibres of the interosseous membrane. The radial tuberosity thereby turns towards the ulna. This movement has an 85° amplitude and is limited by stretching of the interosseous membrane and squeezing of the flexor muscles, again with an elastic end-feel.

Table 1 The flexor muscles

Muscle	Innervation	
	Peripheral	Nerve root
Brachialis	N. musculocutaneus (N. radialis)	C5–C6
Brachioradialis	N. radialis	C5–C6
Brachial biceps	N. musculocutaneus	C5–C6

In full pronation, the concave anterior side of the radius lies posteriorly.

Muscles and tendons

Flexor muscles

The flexor muscles are the brachialis, the brachioradialis and the brachial biceps (Table 1). Their action is maximal when the elbow is flexed at 90°.

Brachialis

This runs from the anterior and distal aspect of the humerus towards the ulnar tuberosity and the joint capsule (Fig. 8). It is a monoarticular muscle. Its only function is to bend the elbow, irrespective of the degree of pronation–supination of the forearm.

Brachioradialis

This muscle has its origin at the lateral supracondylar ridge of the humerus and inserts at the radial aspect of the styloid process of the radius (see Putz, Fig. 351). It brings the pronated or supinated forearm back in the neutral position between pronation and supination. In this position it acts as a flexor of the elbow, an action which diminishes when the forearm is held in supination.

Biceps

This is the dominant flexor of the elbow. It originates from the scapula, where it has two heads, the long head from the supraglenoid tubercle, the short head from the coracoid process, and it inserts with a strong thick tendon at the radial tuberosity (see Putz, Fig. 308). Part of the tendon blends into the aponeurosis of the forearm at the ulnar side (Fig. 9). Because the biceps is a biarticular muscle, it also acts on the shoulder. Its essential function is elbow flexion but its secondary function is supination of the forearm. Such supination action of the biceps increases the more the elbow is flexed and is maximal at 90°; it diminishes again when the elbow is fully flexed.

Extensor muscles

Extension of the elbow is performed by two muscles: the triceps and the anconeus (Table 2).

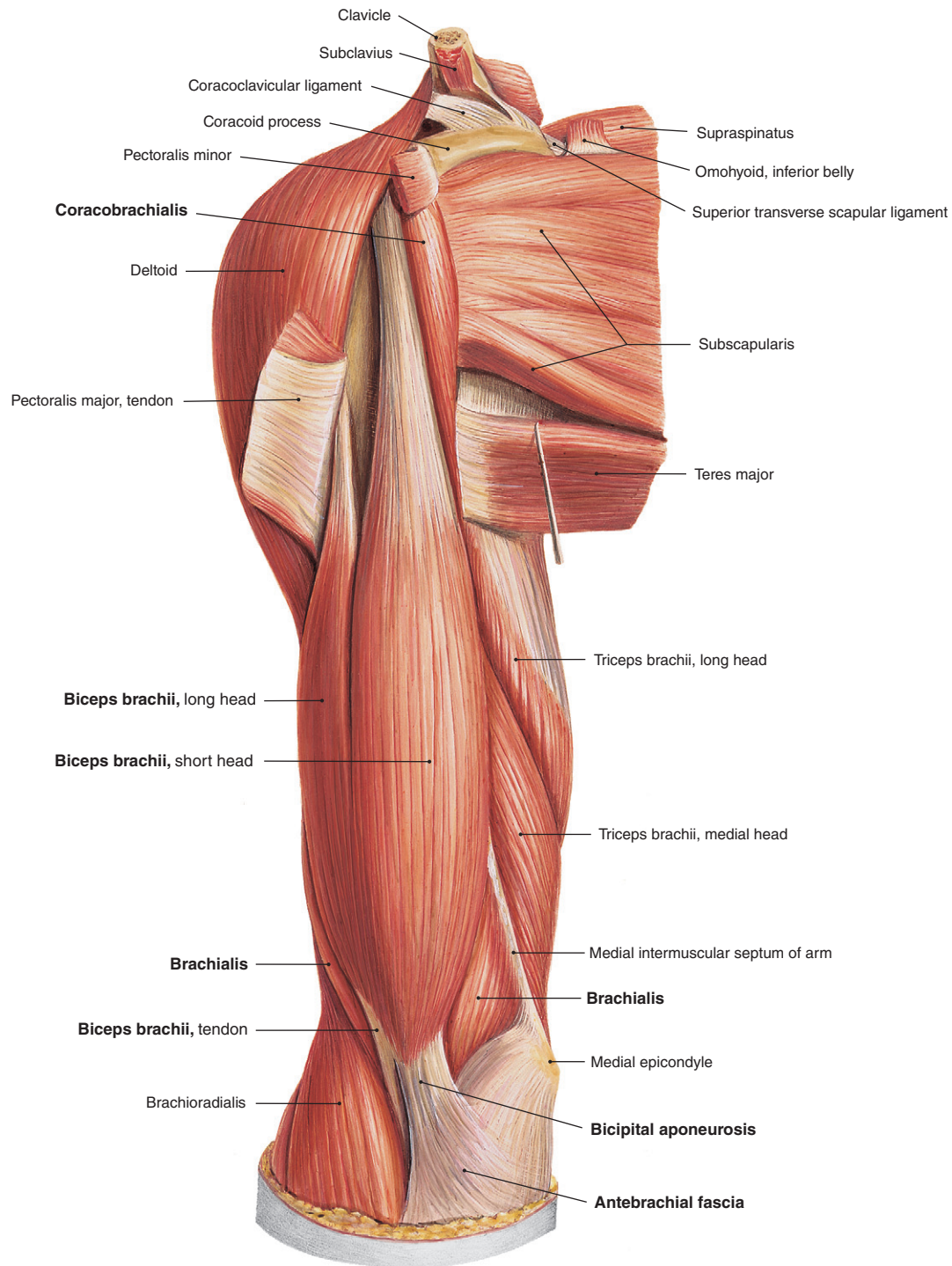


Fig 8 • Flexor muscles of the elbow: brachialis, biceps brachii and brachioradialis. From Putz, Sobotta – Atlas of Human Anatomy, 14th edn. Urban & Fischer/Elsevier, Munich, 2008 with permission.

The triceps

The triceps originates from three heads as its name implies: the long head from the infraglenoid tubercle of the scapula, the medial head from the dorsal aspect of the humerus, distally to the sulcus for the radial nerve, and the lateral head also from the dorsal aspect of the humerus, proximally to that sulcus. The three muscular bodies join in one tendon that inserts at

the olecranon and at the posterior aspect of the joint capsule (Fig. 9).

Because the triceps is partly biarticular, its extension action to the elbow joint depends not only on the position of the elbow but also on the position of the shoulder. The triceps has its maximal force in a movement which combines the two: elbow extension and shoulder extension.

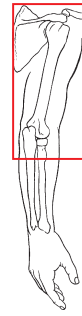
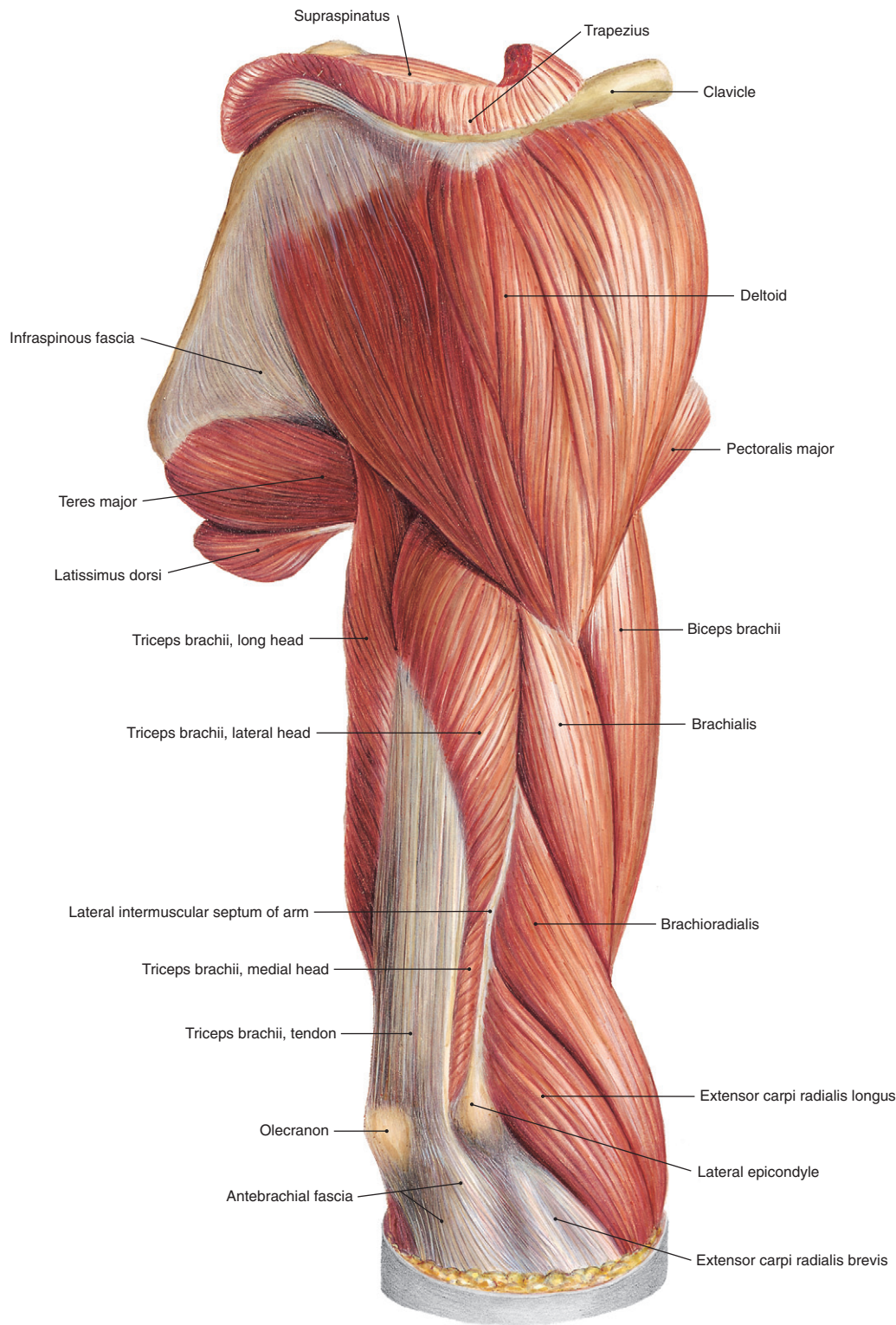


Fig 9 • The triceps: the extensor muscle of the elbow. From Putz, Sobotta – Atlas of Human Anatomy, 14th edn. Urban & Fischer/Elsevier, Munich, 2008 with permission.

Anconeus

Originating at the dorsal aspect of the lateral epicondyle of the humerus and at the lateral collateral ligament, this muscle runs towards the posterior and proximal aspect of the ulna and the

joint capsule. It may be considered as a continuation of the lateral head of the triceps. It thus helps the triceps in its extensor function and also spans the joint capsule. From the clinical point of view this muscle may be ignored.

Table 2 The extensor muscles

Muscle	Innervation	
	Peripheral	Nerve root
Triceps	N. radialis	C7–C8
Anconeus	N. radialis	C7–C8

Table 3 The supinator muscles

Muscle	Innervation	
	Peripheral	Nerve root
Supinator brevis	N. radialis	C5–C6
Brachial biceps	N. musculocutaneus	C5–C6

Table 4 The pronator muscles

Muscle	Innervation	
	Peripheral	Nerve root
Pronator teres	N. medianus	C6–C7
Pronator quadratus	N. interosseus palmaris (N. medianus)	C8–T1

Supinator muscles

Supination movement is the result of the action of two muscles: the supinator brevis and brachial biceps (Table 3).

Supinator brevis

This takes origin at the supinator crest of the ulna, the lateral epicondyle, the radial collateral ligament and the annular ligament. The muscular fibres encircle the radius and insert via a short tendon at the radius between the radial tuberosity and the insertion of the pronator teres muscle (see Putz, Fig. 359). The muscle supinates the forearm in whatever position there is between flexion and extension of the elbow.

Brachial biceps

This is the strongest supinator of the forearm (see above).

Pronator muscles

Pronation is performed by two muscles: the pronator quadratus and the pronator teres (Table 4).

Pronator quadratus

This is at the distal aspect of the forearm. It runs from the distal and anterior part of the ulna to the distal and anterior part of the radius, so encircling the ulna. Its role is dealt with in Section 6.

Table 5 The extensor muscles of the wrist and fingers

Muscle	Innervation	
	Peripheral	Nerve root
Extensor carpi radialis longus	N. radialis	C6–C7
Extensor carpi radialis brevis	N. radialis	C7
Extensor carpi ulnaris	N. radialis	C7–C8
Extensor digitorum communis	N. radialis	C6–C8

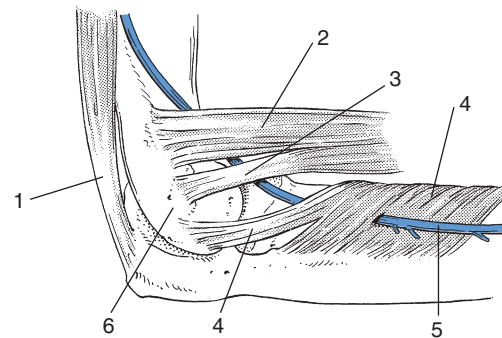


Fig 10 • Lateral view of the extensors of the elbow: 1, triceps muscle; 2, extensor carpi radialis longus muscle; 3, extensor carpi radialis brevis muscle; 4, supinator muscle; 5, radial nerve; 6, lateral epicondyle.

Pronator teres

The pronator teres has a multiple origin: the humeral head from the medial epicondyle of the humerus (partly from the common flexor tendon) and the ulnar head from the coronoid process of the ulna. Its insertion lies halfway down the radius at the lateral aspect (see Putz, Fig. 352). Because the pronator teres is a biarticular muscle, theoretically it also assists in the flexion of the elbow but this action is of course very secondary.

The pronator muscles are not as strong as the supinator muscles.

Muscles controlling wrist movement

Two groups of muscles originate at the elbow but control wrist movements: they are the flexors and extensors of the wrist (and fingers).

Extensors of the wrist and fingers (Table 5, see Standring, Fig. 49.14, see Gosling et al, Fig. 3.70)

Extensor carpi radialis longus

This takes its origin at the lateral supracondylar margin of the humerus, just proximal to the lateral epicondyle and at the lateral intermuscular septum (Fig. 10).

Table 6 The flexor muscles of the wrist and fingers

Muscle	Innervation	
	Peripheral	Nerve root
Flexor carpi radialis	N. medianus	C6–C7
Flexor carpi ulnaris	N. ulnaris	C7–C8
Palmaris longus	N. medianus	C7–T1
Superficial flexor digitorum	N. medianus	C7–T1
Flexor pollicis longus	N. medianus	C7–C8

Extensor carpi radialis brevis

The origin is at the anterior aspect of the lateral epicondyle but the muscle also partly originates from the lateral collateral ligament and from the annular ligament of the radius.

Both muscles run together towards the wrist. They cause extension of the wrist (especially the extensor carpi radialis brevis muscle) as well as radial deviation.

Extensor carpi ulnaris

Running from the dorsal and lateral aspects of the lateral epicondyle, as well as from the radial collateral ligament and the fascia of the forearm towards the wrist, this assists slightly in the extension of the wrist but its main function is ulnar deviation.

Extensor digitorum communis

The origin (together with the extensor carpi ulnaris muscle) is just dorsal to the extensor carpi radialis brevis muscle from the lateral epicondyle, the radial collateral ligament, the annular ligament of the radius and the fascia of the forearm; the muscle runs towards the fingers. Its main function is finger extension but it also assists in extension (and ulnar deviation) of the wrist.

Flexors of wrist and fingers (Table 6, see Standring, Fig. 49.12, see Gosling et al, Fig. 3.72)

The flexors of the wrist and fingers take their origin at the medial epicondyle of the humerus (Fig. 11), mainly in a common flexor tendon which has a superficial and a deep layer. The superficial layer consists of the humeral head of the pronator teres muscle, the flexor carpi radialis, the palmaris longus, the humero-ulnar head of the superficial flexor digitorum and the humeral head of the flexor carpi ulnaris.

Flexor carpi radialis

Starting at the anterior aspect of the medial epicondyl, this muscle runs towards the wrist. Its main function is flexion of the wrist; its radial deviation function is secondary.

Flexor carpi ulnaris

Starting with a humeral head at the medial epicondyle, this also has an ulnar head at the olecranon and the upper part of the posterior margin of the ulna. It flexes the wrist and assists

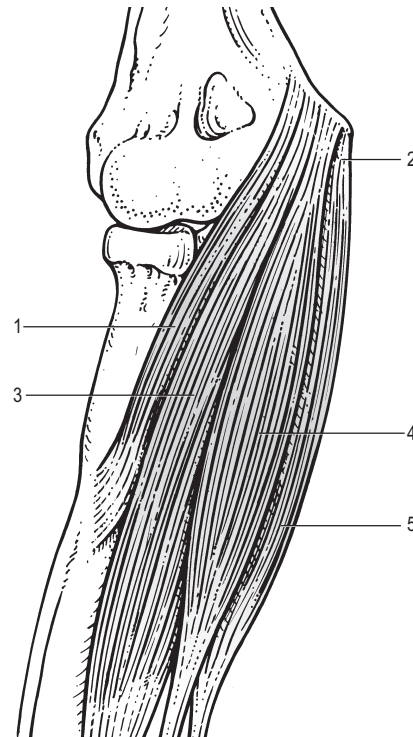


Fig 11 • Muscles originating at the medial epicondyle (anterior aspect): 1, pronator teres muscle; 2, common flexor tendon; 3, flexor carpi radialis muscle; 4, palmaris longus muscle; 5, flexor carpi ulnaris muscle.

the extensor carpi ulnaris in performing ulnar deviation of the wrist.

Palmaris longus

This is not always present. When it is, it runs towards the hand into the palmar aponeurosis, of which it is a tensor. It also helps in flexion of the wrist.

Superficial flexor digitorum

The origin is threefold: a humeral head originating from the common flexor tendon at the medial epicondyle of the humerus, an ulnar head from the coronoid process and a radial head from the anterior aspect of the radius. Apart from flexion of the fingers, it also assists in ulnar deviation of the wrist.

Flexor pollicis longus

This lies in the deeper layer. It has a humeral head, originating from the medial epicondyle and, more important, a radial head originating from the anterior aspect of the radius, just distal to the supinator muscle and the interosseous membrane. It flexes the thumb and assists in flexion of the wrist.

Nerves

The nervous structures are discussed here because entrapment may occur in the elbow region. Only the appropriate part of

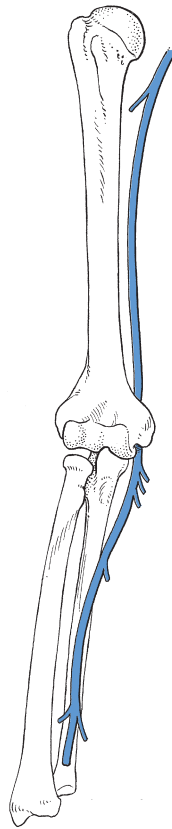


Fig 12 • The course of the ulnar nerve.

the nerve is described. For a more extensive description, see online chapter *Nerve lesions and entrapment neuropathies of the upper limb*.

Ulnar nerve

The ulnar nerve courses under the medial head of the triceps muscle towards the posterior aspect of the medial epicondyle, where it lies superficially in a shallow groove behind this bone (sulcus for the ulnar nerve; Fig. 12) and is, therefore, very vulnerable to direct contusion. It becomes stretched during flexion of the elbow. The nerve runs further distally in between the two heads of the flexor carpi ulnaris muscle, which form an aponeurotic arch. Together with the medial epicondyle, the olecranon and the medial collateral ligament, this arch forms the 'cubital tunnel' (Fig. 13, see Putz, Fig. 410).

Median nerve

At the elbow, the median nerve is of lesser clinical significance, because it is seldom affected at this level. In the upper arm, the nerve courses between the radial and the ulnar nerves. It passes through the antecubital fossa just medially to the bicipital tendon and beneath its aponeurosis. It lies between the two heads of the pronator teres muscle and runs further under a tendinous arch connecting the heads of the superficial flexor digitorum muscle (Fig. 14, see Putz, Fig. 409).

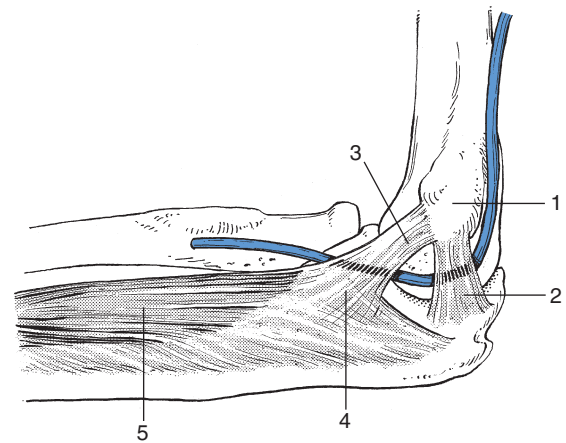


Fig 13 • The course of the ulnar nerve through the cubital tunnel: 1, medial epicondyle; 2, medial collateral ligament (posterior part); 3, common flexor tendon; 4, aponeurotic arch; 5, flexor carpi ulnaris muscle.

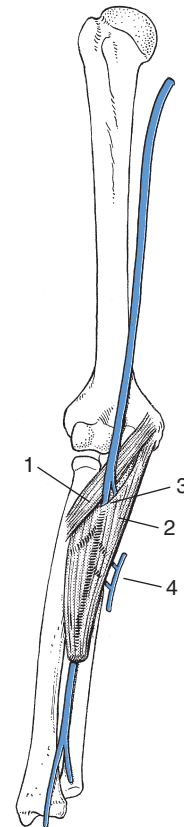


Fig 14 • The course of the median nerve: 1, pronator teres muscle; 2, superficial flexor digitorum muscle; 3, tendinous arch; 4, Martin-Grüber anastomosis with the ulnar nerve.

The median nerve is liable to anomalies consisting of either communications with other nerves or unusual branching. The commonest anomaly is the Martin-Grüber anastomosis: one or more branches from the median nerve pass to the ulnar nerve in the forearm. The practical consequence of this is that a

median nerve palsy may involve the intrinsic hand muscles and that ulnar nerve disorders may spare the muscles usually innervated by it.

Medial cutaneous nerve of the forearm

This nerve becomes superficial at mid-arm as it runs through an opening in the brachial fascia, the basilic hiatus, and supplies the skin from the inner aspect of the elbow as far as the wrist. In the elbow region, it crosses over the median basilic vein and lies in a position where it is subject to injury by an accidental extraveneous injection.

Radial nerve

In the distal part of the upper arm, the radial nerve lies lateral to the median nerve. It courses between the bicipital tendon and the proximal part of the brachioradialis muscle.

Level with the head of the radius the nerve then divides into a deep motor branch (the deep radial nerve), from which the posterior interosseous nerve branches off a bit further down, and a superficial sensory branch (the superficial radial nerve) (Fig. 15, see Putz, Fig. 411).

The posterior interosseous nerve turns around the neck of the radius and comes to lie at the dorsal aspect of the forearm where it passes through an opening in the supinator muscle: the arcade of Fröhse, formed by the edge of the upper border of the superficial part of this muscle. At this location (the

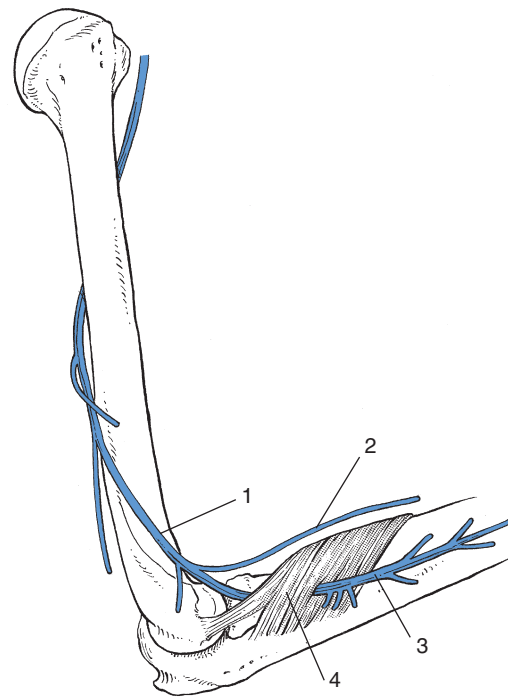


Fig 15 • The course of the radial nerve: 1, radial nerve; 2, superficial radial nerve (sensory); 3, posterior interosseous nerve (motor); 4, arcade of Fröhse in the supinator muscle (forming the 'radial tunnel').

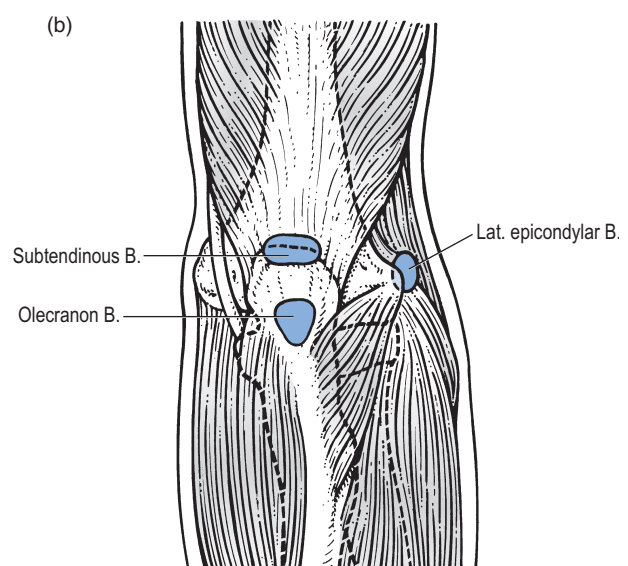
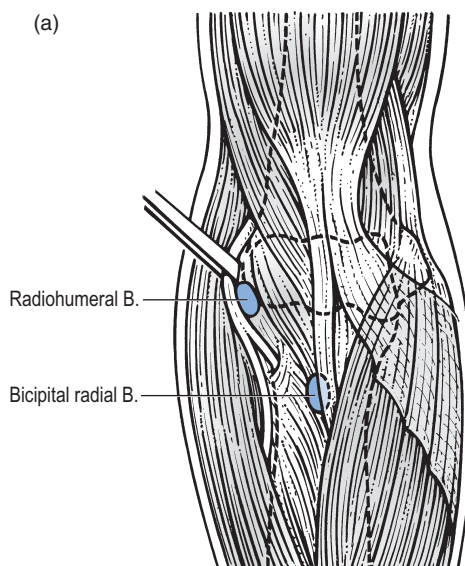


Fig 16 • (a and b) Bursae of the elbow.

‘radial tunnel’) it may sometimes be compressed and cause radial tunnel syndrome (see online chapter *Nerve lesions and entrapment neuropathies of the upper limb*).

Bursae

Bursae are regularly found: in the region of the insertion of the triceps into the olecranon (subcutaneous olecranon bursa and

subtendinous tricipital bursa); under the biceps tendon at its attachment to the radial tuberosity; and at the lateral aspect of the elbow, where both superficial epicondylar and radio-humeral bursae occur (Fig. 16).